



# Coronavirus disease 2019, vaccination against coronavirus and immunoglobulin A-mediated diseases: systematic literature review

Gabriel Bronz<sup>a,1</sup>, Pietro B. Faré<sup>b,1</sup>, Sebastiano A.G. Lava<sup>c,d</sup>, Mario G. Bianchetti<sup>e,f</sup>, Giacomo D. Simonetti<sup>a,f</sup>, Martin Scoglio<sup>e</sup>, Benedetta Terziroli Beretta-Piccoli<sup>f,g,\*</sup>, Carlo Agostoni<sup>h,i</sup>, Gregorio P. Milani<sup>h,i</sup>

<sup>a</sup> Pediatric Institute of Southern Switzerland, Ente Ospedaliero Cantonale, Bellinzona, Switzerland

<sup>b</sup> Division of Infectious Diseases, Department of Medicine, Ente Ospedaliero Cantonale, Lugano, Switzerland

<sup>c</sup> Pediatric Cardiology Unit, Department of Pediatrics, Centre Hospitalier Universitaire Vaudois and University of Lausanne, Lausanne, Switzerland

<sup>d</sup> Heart Failure and Transplantation, Department of Paediatric Cardiology, Great Ormond Street Hospital, London, United Kingdom

<sup>e</sup> Family Medicine, Faculty of Biomedical Sciences, Università Della Svizzera Italiana, Lugano, Switzerland

<sup>f</sup> Faculty of Biomedical Sciences, Università Della Svizzera Italiana, Lugano, Switzerland

<sup>g</sup> Epatocentro Ticino, Lugano, Switzerland

<sup>h</sup> Pediatric Unit, Fondazione IRCCS Ca' Granda Ospedale Maggiore Policlinico, Milan, Italy

<sup>i</sup> Department of Clinical Sciences and Community Health, Università Degli Studi di Milano, Milan, Italy

## ARTICLE INFO

### Keywords:

Berger glomerulonephritis  
Coronavirus 2019  
COVID 19  
Henoch-schönlein vasculitis  
Immunoglobulin A nephritis  
Immunoglobulin A vasculitis  
Vaccination  
SARS-CoV-2

## ABSTRACT

Coronavirus disease 2019 (COVID-19) and vaccination against severe acute respiratory syndrome coronavirus 2 (SARS-CoV-2) have been associated with autoimmune phenomena. However, the interplay between COVID-19 or vaccination against SARS-CoV-2 and Berger glomerulonephritis or Henoch-Schönlein vasculitis, two diseases mediated by immunoglobulin A, has never been comprehensively investigated. Therefore, we carried out a systematic review of the literature on this topic. Following databases were used: Google Scholar, Excerpta Medica and the United States National Library of Medicine. Eighty-seven patients with immunoglobulin A-mediated diseases associated with SARS-CoV-2 infection or vaccination against coronavirus were sorted out (53% males, 47% females; 34 17-51 years of age, median and interquartile range): 47 cases of Berger glomerulonephritis and 40 of Henoch-Schönlein vasculitis. Approximately 50% (N = 24) of Berger glomerulonephritis and 10% (N = 4) of Henoch-Schönlein vasculitis patients presented with a pre-existing history of immunoglobulin A-mediated disease. Almost all cases of Berger glomerulonephritis were vaccine-associated (N = 44; 94%), while most cases of Henoch-Schönlein vasculitis were infection-associated (N = 23; 57%). Among vaccine-associated immunoglobulin A diseases, about 90% were associated to mRNA-based vaccines. Our analysis supports the hypothesis that COVID-19 and vaccination against SARS-CoV-2 may trigger or exacerbate an immunoglobulin A-mediated diseases.

## 1. Introduction

Henoch-Schönlein vasculitis and Berger glomerulonephritis are characterized by tissue deposition of immunoglobulin A [1,2]. The onset of Henoch-Schönlein vasculitis [1] is often preceded by a common respiratory disease or a vaccination. Similarly, both the acute onset and the recurrences of Berger glomerulonephritis, may be preceded by a respiratory disease or a vaccination [2].

Coronavirus disease 2019 (COVID-19) and vaccination against severe acute respiratory syndrome coronavirus 2 (SARS-CoV-2) may trigger autoimmune phenomena [3]. However, little is known about the interplay between SARS-CoV-2 and immunoglobulin A-mediated diseases. Hence, we carried out a systematic review of the literature to determine whether COVID-19 or vaccination against SARS-CoV-2 may be temporally related to a new-onset, or a flare, of an immunoglobulin A-mediated disorder.

*Abbreviations:* COVID-19, Coronavirus disease 2019; SARS-CoV-2, Severe acute respiratory syndrome coronavirus 2.

\* Corresponding author. Faculty of Biomedical Sciences, Università Della Svizzera Italiana, Lugano, Switzerland.

*E-mail address:* [benedetta.terziroli@hin.ch](mailto:benedetta.terziroli@hin.ch) (B.T. Beretta-Piccoli).

<sup>1</sup> These authors contributed equally.

<https://doi.org/10.1016/j.jaut.2022.102899>

Received 17 July 2022; Received in revised form 14 August 2022; Accepted 14 August 2022

Available online 22 August 2022

0896-8411/© 2022 The Authors. Published by Elsevier Ltd. This is an open access article under the CC BY license (<http://creativecommons.org/licenses/by/4.0/>).

## 2. Methods

### 2.1. Search strategy

This review was undertaken in agreement with the 2020 edition of the Preferred Reporting Items for Systematic Reviews and Meta-Analyses methodology [4]. Google Scholar, Excerpta Medica and the United States National Library of Medicine were explored in March 2022 (and before submission) without limitations for original articles or letters using following terms entered in separate pairs: “anaphylactoid purpura” OR “Henoch-Schönlein” OR “Henoch” OR “IgA purpura” OR “IgA vasculitis” OR “immunoglobulin A purpura” OR “immunoglobulin A vasculitis” OR “rheumatoid purpura” OR “Henoch-Schönlein” OR “Berger disease” OR “Berger nephritis” OR “Berger glomerulonephritis” OR “immunoglobulin A nephritis” AND “coronavirus disease 2019” OR “COVID-19” OR “severe acute respiratory syndrome coronavirus 2” OR “SARS-CoV-2”. References listed within bibliographies of the retrieved records and articles already known to the authors were also considered for inclusion.

### 2.2. Selection criteria – diagnostic criteria

Of interest were cases of immunoglobulin A-mediated diseases preceded by COVID-19 or a vaccination against SARS-CoV-2 with a latency of four weeks or less. The time latency from symptomatic COVID-19 to onset of immunoglobulin A-mediated disease was calculated based on the onset of symptoms or signs. Cases preceded by an infection other than SARS-CoV-2 or by a vaccination against a microorganism other than SARS-CoV-2 with a latency of four weeks or less were excluded. The diagnosis of Henoch-Schönlein vasculitis [1] was made in subjects with palpable purpura and at least one of the following features: abdominal pain, acute arthritis or arthralgia in any joint, and kidney involvement as evidenced by hematuria (with or without associated pathological proteinuria). A biopsy study was not a prerequisite for the diagnosis of Henoch-Schönlein vasculitis. The diagnosis of Berger glomerulonephritis [2] was made in patients with acute onset of otherwise unexplained gross hematuria and proteinuria supported, if possible, by histologic and immunochemical evidence.

The diagnosis of new onset Henoch-Schönlein vasculitis or Berger glomerulonephritis temporally associated with COVID-19 or vaccination against SARS-CoV-2 was retained in subjects without a history of the mentioned conditions. On the other hand, the diagnosis of Henoch-Schönlein vasculitis flare or Berger glomerulonephritis flare was retained in subjects with a history of the mentioned conditions. Cases of Henoch-Schönlein vasculitis or acute Berger glomerulonephritis temporally associated with COVID-19 were categorized as intra-(immunoglobulin A-mediated disease starting or flaring before resolution of COVID-19) or post-infectious (immunoglobulin A-mediated disease after resolution of COVID-19).

A positive microbiologic testing was a prerequisite for the diagnosis of COVID-19. Its severity was categorized in five stages as recommended by the National Institutes of Health: 1. Asymptomatic (without signs and symptoms but recent strict contact to symptomatic cases); 2. mild (any sign or symptom such as fever, cough, sore throat, malaise, headache, muscle pain without shortness of breath, dyspnea, or abnormal chest imaging); 3. moderate (evidence of lower respiratory disease by clinical assessment or imaging, and transcutaneous O<sub>2</sub>-saturation  $\geq 94\%$  on room air); 4. severe illness (breathing rate  $>30$ /minute, O<sub>2</sub>-saturation  $<94\%$  on room air, or pulmonary infiltrates  $>50\%$ ); 5. critical (hypercapnic respiratory failure, septic shock, or multiple organ dysfunction).

### 2.3. Data extraction

For each case of new onset or flare of an immunoglobulin A-mediated disease temporally related to COVID-19, following information was collected: medical history with emphasis on a pre-existing

immunoglobulin A-mediated disease; presentation and duration of the immunoglobulin A-mediated disease, testing for COVID-19; temporal relationship between COVID-19 and onset of immunoglobulin A-mediated disease. Similarly, for each case of new onset or flare of immunoglobulin A-mediated disease preceded by a vaccination against coronavirus, following information was collected: medical history with emphasis on a pre-existing immunoglobulin A-mediated disease; presentation and duration of the immunoglobulin A-mediated disease, type of vaccine and dose (first, second, or third); temporal relationship between vaccination and first symptoms and signs of immunoglobulin A-mediated disease.

Attempts also were made to contact original authors to acquire missing data. Two authors independently carried out the literature search, the selection of articles retained for analysis and the data extraction. One author entered the data into a pilot-tested database, and the second author verified the accuracy of data entry. Discrepancies were resolved by consensus and, where necessary, a third author was consulted.

### 2.4. Analysis

Pairwise deletion was used to deal with missing data that were not obtained from the corresponding authors. Categorical data are presented as counts and were analyzed using the Fisher exact test. Continuous data are shown as medians and interquartile ranges and were compared using the Mann-Whitney-Wilcoxon test. Statistical significance was defined by two-sided P-values of  $<0.05$ .

## 3. Results

### 3.1. Search results

The literature search returned 2570 potentially relevant records (Fig. 1). In the first selection round, reports were screened based on titles and abstracts. In the second selection round, full-text articles of the remaining papers were assessed. For the final analysis, we retained 68 reports [5–72]: 25 from Europe (France, N = 7; Spain, N = 5; Italy, N = 4; Turkey, N = 3; Switzerland, N = 2; United Kingdom, N = 2; Germany, N = 1; Luxemburg, N = 1), 17 from North America (United States of America, N = 15; Canada, N = 1; Mexico, N = 1), 20 from Asia (Japan, N = 9; India, N = 3; Jordan, N = 2; Bahrain, N = 1; Islamic Republic of Iran, N = 1; Israel, N = 1; Lebanon, N = 1; People's Republic of China, N = 1; Singapore, N = 1), two from Africa (Egypt, N = 1; Morocco, N = 1), two from Oceania (Australia, N = 2) and two from South America (Brazil, N = 1; Peru, N = 1). They were published in English (N = 65) and Spanish (N = 3).

## 4. Findings

### 4.1. General findings

The reports provided information on 87 cases: 47 cases of Berger glomerulonephritis [5–32] and 40 cases of Henoch-Schönlein [33–72] vasculitis (Table 1). Henoch-Schönlein and Berger cases did not significantly differ with respect to age and female to male ratio. Twenty-eight cases occurred in patients with medical history of an immunoglobulin A-mediated disease: this trend was significantly ( $P = 0.0001$ ) more common in Berger glomerulonephritis (N = 24; 51%) than in Henoch-Schönlein vasculitis (N = 4; 10%). A pre-existing autoimmune disease was present in six cases: rheumatoid arthritis in two [36,40], and antiphospholipid syndrome [14], Crohn disease [52], Hashimoto thyroiditis [39] or ulcerative colitis [25] in each one case.

Approximately three out of four cases were preceded by a vaccination: this tendency was more common ( $P = 0.0001$ ) in Berger glomerulonephritis (N = 44; 94%) than in Henoch-Schönlein vasculitis (N = 17; 43%). The time latency from precursor was similar in Henoch-Schönlein

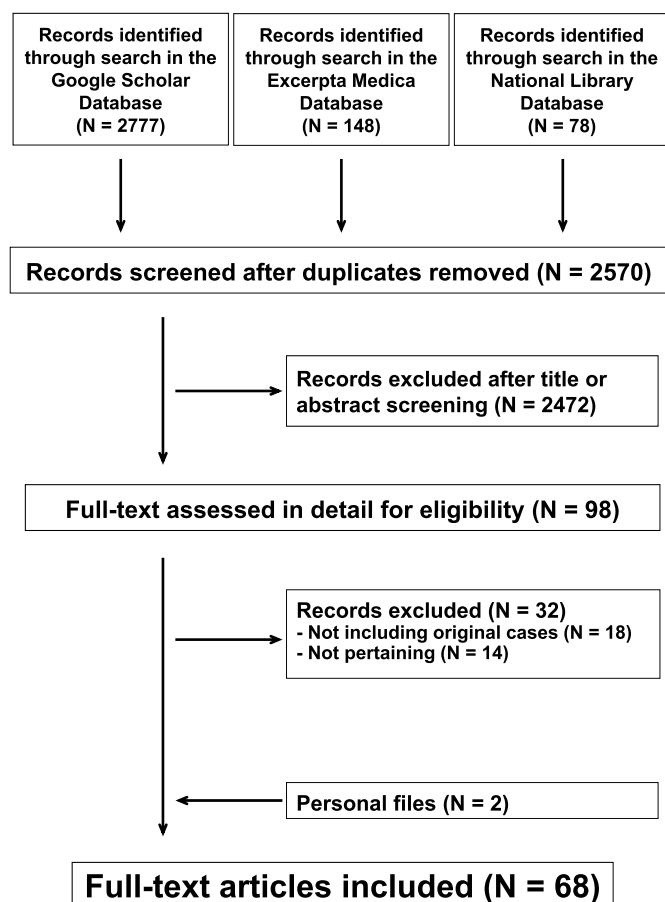


Fig. 1. Legend Flowchart of the literature search process.

vasculitis and in Berger glomerulonephritis (Table 1). The disease duration was more frequently >4 weeks in Berger glomerulonephritis than in Henoch-Schönlein vasculitis ( $P = 0.0362$ ).

The test employed for the diagnosis of COVID-19 was a polymerase chain reaction in 24 (Henoch-Schönlein vasculitis,  $N = 21$ ; Berger glomerulonephritis,  $N = 3$ ) and a specific serology validated for the diagnosis of an acute coronavirus infection [73] in two patients with

Henoch-Schönlein vasculitis. Two cases presented with a critical, two with a severe, three with a moderate, 13 with a mild and five with an asymptomatic COVID-19 (this piece of information was not available for one case). The immunoglobulin A-mediated disease was intra-infectious in 20 (Henoch-Schönlein vasculitis,  $N = 18$ ; Berger glomerulonephritis,  $N = 2$ ) and post-infectious in the remaining 6 cases (Henoch-Schönlein vasculitis,  $N = 5$ ; Berger glomerulonephritis,  $N = 1$ ).

About 90% of vaccine-associated cases (Table 2) occurred after a mRNA-1273 or a mRNA-BNT162b2 vaccine. Forty cases were observed after the second (Berger glomerulonephritis,  $N = 34$ ; Henoch-Schönlein vasculitis,  $N = 6$ ) and 13 after the first dose (Henoch-Schönlein vasculitis,  $N = 7$ ; Berger glomerulonephritis,  $N = 6$ ) of vaccine. No case was observed after the third vaccine dose. In seven cases, the disease occurred both after the first and the second vaccine dose (Henoch-Schönlein vasculitis,  $N = 4$ ; Berger glomerulonephritis,  $N = 3$ ). No information on the vaccine dose was available in the remaining case of Henoch-Schönlein vasculitis.

#### 4.2. Henoch-Schönlein vasculitis

Henoch-Schönlein vasculitis was associated with a kidney involvement in 50% ( $N = 20$ ) of cases. It was vaccine-associated in about 40% and infection-associated in the remaining 60% of cases (Table 3). Vaccine-associated cases were older ( $P = 0.0008$ ), occurred after a longer latency time ( $P = 0.048$ ) and presented less frequently ( $P = 0.022$ ) with an abdominal involvement than infection-associated cases. In contrast, no significant differences were noted between vaccine- and infection-associated cases with respect to gender, prevalence of pre-

Table 2

Vaccines against severe acute respiratory syndrome coronavirus 2 implicated in Berger glomerulonephritis and Henoch-Schönlein vasculitis.

	All	Berger Glomerulonephritis	Henoch-Schönlein Vasculitis
mRNA - BNT162b2	28	23	5
mRNA - 1273	23	19	4
ChadOx1 nCoV-19	6	0	6
mRNA based COVID-19 vaccine <sup>a</sup>	2	2	0
Ad26.COV2-S	1	0	1
Inactivated COVID-19 vaccine <sup>a</sup>	1	0	1

<sup>a</sup> not otherwise specified.

Table 1

Characteristics of 87 patients with an immunoglobulin A-mediated disease preceded by a coronavirus disease 2019 or a vaccination against severe acute respiratory syndrome coronavirus 2. Data are presented as frequency or as median with interquartile range.

	All	Berger Glomerulonephritis	Henoch-Schönlein Vasculitis	P-value
N	87	47	40	
Males: females, N	45 : 40	20 : 25	25 : 15	0.128
Age				
years	34 [17–51]	35 [19–46]	33 [13–65]	0.881
≤18 years, N	23	10	13	0.812
Underlying autoimmune diseases <sup>◆</sup> , N	6	2	4	0.9999
Immunoglobulin A mediated disease				0.0001
Pre-existing, N	28	24 <sup>°</sup>	4 <sup>¶</sup>	
De novo, N	59	23 <sup>‡</sup>	36 <sup>Δ</sup>	
Precursor				0.0001
Infection, N	26	3	23	
Vaccination, N	61	44	17	
Time latency, days	2 [1–9]	2 [1–5]	3 [1–10]	0.178
Disease duration >4 weeks, N	25	18	7	0.0362

<sup>a</sup> The diagnosis of Henoch-Schönlein vasculitis was supported by a kidney biopsy in one case (no skin biopsy was performed); <sup>◆</sup> other than immunoglobulin A-mediated diseases; <sup>°</sup> the diagnosis of Berger glomerulonephritis was supported by a kidney biopsy in the 24 cases; <sup>Δ</sup> the diagnosis of de novo Henoch-Schönlein vasculitis was supported by a biopsy in 23 of the 36 cases: skin biopsy,  $N = 16$ ; both skin and kidney biopsy,  $N = 7$ ; <sup>‡</sup> the diagnosis of de novo Berger glomerulonephritis was supported by a kidney biopsy in 21 of the 23 cases with new onset glomerulonephritis.

**Table 3**

Clinical features of 40 cases of Henoch-Schönlein vasculitis preceded by a coronavirus disease 2019 or a vaccination against severe acute respiratory syndrome coronavirus 2. Data are presented as frequency or as median with interquartile range.

	Vaccination-associated	Infection-associated	P-value
N	17	23	
Males: females, N	9 : 8	16 : 7	0.503
Age, years of age	60 [40–70]	13 [7–30]	0.0008
Latency, days	8 [2–11]	3 [0–9]	0.048
Henoch-Schönlein vasculitis			0.294
Pre-existing, N	3	1	
De novo, N	14	22	
Extracutaneous involvement			
Abdominal, N	3	13	0.022
Articular, N	6	12	0.347
Renal, N	9	9	0.523
Disease duration >4 weeks, N	2	5	0.677

**Table 4**

Clinical features of 47 cases of Berger glomerulonephritis preceded by a coronavirus disease 2019 or a vaccination against severe acute respiratory syndrome coronavirus 2. Data are presented as frequency or as median with interquartile range (vaccination-associated cases) or as individual values (infection-associated cases). Information on sex was not available in two vaccination-associated cases.

	Vaccination-associated	Infection-associated
N	44	3
Males: females, N	18 : 24	2 : 1
Age, years of age	33 [19–45]	18; 65; 88
Latency, days	2 [1–4]	1; 3; 21
Berger glomerulonephritis		
Pre-existing, N	24	0
De novo, N	20	3
Disease duration >4 weeks, N	16	2

existing Henoch-Schönlein vasculitis, articular or renal involvement, and disease duration.

#### 4.3. Berger glomerulonephritis

As previously stated, all but three cases (94%) of Berger glomerulonephritis were vaccine-associated (Table 4). Approximately 55% of cases had a history of pre-existing Berger glomerulonephritis. Most cases remitted within 4 weeks.

## 5. Discussion

This review documents 87 patients, mostly adults, with 94 cases of immunoglobulin A-mediated diseases, which were temporally associated with a vaccination against SARS-CoV-2 (mostly a mRNA vaccine) or, less frequently, with COVID-19. Two-thirds of cases occurred in subjects without history of a pre-existing immunoglobulin A-mediated disease. Furthermore, most cases were benign, as indicated by the fact that they remitted within 4 weeks [1,2]. Moreover, almost all published cases of Berger glomerulonephritis were vaccine- while most Henoch-Schönlein cases were infection-associated. Finally, immunoglobulin A disease occasionally occurred both after the first and the second vaccine dose, further supporting not only a temporal but also a causal relationship.

The mechanisms by which COVID-19 or vaccination against SARS-CoV-2 predispose to autoimmune phenomena including immunoglobulin A-mediated disease are currently unclear. However, SARS-CoV-2 shares with Epstein-Barr virus and many common respiratory tract

viruses features that may trigger autoimmunity including superantigen activity, functional and molecular mimicry, and activation of inflammatory signaling [3]. The occurrence of an immunoglobulin A-mediated disease in association with COVID-19 or vaccination against SARS-CoV-2 is likely explained by the fact that an immunoglobulin A response is observed three days or more after disease onset [73,74] or vaccination [74,75]. In immunoglobulin A-mediated diseases, the initiating event is the deposition of aberrantly glycosylated immunoglobulin A1 containing polymeric immune complexes, which are larger and contain a higher concentration of immunoglobulin E in Henoch-Schönlein vasculitis than in Berger glomerulonephritis [1]. Little is known about the overall incidence of immunoglobulin A-mediated diseases during the pandemic. However, limited evidence suggests a decreased incidence of Henoch-Schönlein vasculitis in childhood [76,77].

Vaccine-associated immunoglobulin A mediated diseases were mostly observed after a mRNA vaccine. The link is likely explained either by the fact that these vaccines are used very often or/and by the fact that they are strongly immunogenic [77].

The major novelty of the present observations lies in the ability to demonstrate a possible causal association between COVID-19 or vaccination against SARS-CoV-2 and immunoglobulin A-mediated diseases. In contrast, information from case reports is prone to bias, cannot be inferred to determine prevalence and cannot be extrapolated to general experience [75,78]. For example, the present data do not prove that fewer cases of immunoglobulin A disease occur after COVID-19 than after vaccination against SARS-CoV-2. Although Henoch-Schönlein vasculitis mostly affects children [1], Henoch-Schönlein patients included in this survey were frequently adult. This likely results from publication bias and from the fact that COVID-19 rarely affects children and that this age group infrequently gets vaccinated against SARS-CoV-2 [76,79].

## 6. Conclusion

These data suggest that SARS-CoV-2 infection and vaccination against SARS-CoV-2 add to the list of triggers of immunoglobulin A diseases. Considering that the outcome of COVID-19 is more severe in subjects with aberrant immune response, they should continue to be offered the vaccine, but warrant close monitoring.

## Author contribution

G.B., P-B.F., S.A.G.L., G.D.S., M.G.B., and G.P.M. conceptualized the study design; G.B., and P.B.F. carried out the literature search; G.B. and P-B.F. extracted and analyzed the data; G.B., S.A.G.L., M.G.B. and G.P.M. wrote the manuscript; G.D.S, M.S., B.T.B-P., and C.A. reviewed the manuscript for important intellectual content; all authors accepted the final version of the manuscript.

## References

- [1] S.A.G. Lava, G.P. Milani, E.F. Fossali, G.D. Simonetti, C. Agostoni, M.G. Bianchetti, Cutaneous manifestations of small-vessel leukocytoclastic vasculitides in childhood. *Clin. Rev. Allergy Immunol.* 53 (3) (2017) 439–451, <https://doi.org/10.1007/s12016-017-8626-3>.
- [2] M.F. Soares, I.S. Roberts, IgA nephropathy: an update. *Curr. Opin. Nephrol. Hypertens.* 26 (3) (2017) 165–171, <https://doi.org/10.1097/MNH.0000000000000312>.
- [3] J.S. Knight, R. Caricchio, J.L. Casanova, A.J. Combes, B. Diamond, S.E. Fox, D. A. Hanauer, J.A. James, Y. Kanthi, V. Ladd, P. Mehta, A.M. Ring, I. Sanz, C. Selmi, R.P. Tracy, P.J. Utz, C.A. Wagner, J.Y. Wang, W.J. McCune, The intersection of COVID-19 and autoimmunity, *J. Clin. Invest.* 131 (24) (2021), e154886, <https://doi.org/10.1172/JCI154886>.
- [4] M.J. Page, J.E. McKenzie, P.M. Bossuyt, I. Boutron, T.C. Hoffmann, C.D. Mulrow, L. Shamseer, J.M. Tetzlaff, E.A. Akl, S.E. Brennan, R. Chou, J. Glanville, J. M. Grimshaw, A. Hróbjartsson, M.M. Lalu, T. Li, E.W. Loder, E. Mayo-Wilson, S. McDonald, L.A. McGuinness, L.A. Stewart, J. Thomas, A.C. Tricco, V.A. Welch, P. Whiting, D. Moher, The PRISMA 2020 statement: an updated guideline for

- reporting systematic reviews, *J. Clin. Epidemiol.* 134 (2021) 178–189, <https://doi.org/10.1016/j.jclinepi.2021.03.001>.
- [5] D.H. Abdel-Qader, I. Hazza Alkhatatbeh, W. Hayajneh, H. Annab, A.Z. Al Meslamani, R.A. Elmusa, IgA nephropathy in a pediatric patient after receiving the first dose of Pfizer-BioNTech COVID-19 vaccine, *Vaccine* 40 (18) (2022) 2528–2530, <https://doi.org/10.1016/j.vaccine.2022.03.003>.
- [6] M. Abramson, S. Mon-Wei Yu, K.N. Campbell, M. Chung, F. Salem, IgA nephropathy after SARS-CoV-2 vaccination, *Kidney Med* 3 (5) (2021) 860–863, <https://doi.org/10.1016/j.xkme.2021.05.002>.
- [7] M. Alonso, F. Villanego, Ó. Segurado, L.A. Vigara, C. Orellana, T. García, A. Mazuecos, De novo IgA nephropathy in a kidney transplant recipient after SARS-CoV-2 vaccination, *Nefrologia* (2021), <https://doi.org/10.1016/j.nefro.2021.11.002> (Epub ahead of print).
- [8] M.A. Anderegg, M. Liu, C. Saganas, M. Montani, B. Vogt, U. Huynh-Do, D.G. Fuster, De novo vasculitis after mRNA-1273 (Moderna) vaccination, *Kidney Int.* 100 (2) (2021) 474–476, <https://doi.org/10.1016/j.kint.2021.05.016>.
- [9] P. Díez Arias, A. Fernández Ramos, P. Ruano, C. Sánchez, B. Quiroga, Hematuria after COVID-19 vaccination: a case report, *Clin. Nephrol.* 97 (2022) 252–254, <https://doi.org/10.5414/CN110562>.
- [10] Y. Fujita, K. Yoshida, D. Ichikawa, Y. Shibagaki, M. Yazawa, Abrupt worsening of occult IgA nephropathy after the first dose of SARS-CoV-2 vaccination, *CEN Case Rep* 6 (2022) 1–7, <https://doi.org/10.1007/s13730-021-00670-2>.
- [11] C. Hanna, L.P. Herrera Hernandez, L. Bu, S. Kizilbash, L. Najera, M.N. Rheault, J. Czyzyk, A.M. Kouri, IgA nephropathy presenting as macroscopic hematuria in 2 pediatric patients after receiving the Pfizer COVID-19 vaccine, *Kidney Int.* 100 (3) (2021) 705–706, <https://doi.org/10.1016/j.kint.2021.06.032>.
- [12] T. Horino, IgA nephropathy flare-up following SARS-CoV-2 vaccination, *QJM* 114 (10) (2021) 735–736, <https://doi.org/10.1093/qjmed/hcab223>.
- [13] N. Klomjit, M.P. Alexander, F.C. Fervenza, Z. Zoghby, A. Garg, M.C. Hogan, S. H. Nasr, M.A. Minshar, L. Zand, COVID-19 vaccination and glomerulonephritis, *Kidney Int Rep* 6 (12) (2021) 2969–2978, <https://doi.org/10.1016/j.ekir.2021.09.008>.
- [14] S. Kudose, P. Friedmann, O. Albajrami, V.D. D'Agati, Histologic correlates of gross hematuria following Moderna COVID-19 vaccine in patients with IgA nephropathy, *Kidney Int.* 100 (2) (2021) 468–469, <https://doi.org/10.1016/j.kint.2021.06.011>.
- [15] L.C.Y. Leong, W.Z. Hong, P. Khatri, Reactivation of minimal change disease and IgA nephropathy after COVID-19 vaccination, *Clin Kidney J* (2021) sfab241, <https://doi.org/10.1093/ckj/sfab241>.
- [16] W.K. Lo, K.W. Chan, Gross haematuria after mRNA COVID-19 vaccination in two patients with histological and clinical diagnosis of IgA nephropathy, *Nephrology* 27 (1) (2022) 110–111, <https://doi.org/10.1111/nep.13992>.
- [17] K. Morisawa, M. Honda, Two patients presenting IgA nephropathy after COVID-19 vaccination during a follow-up for asymptomatic hematuria, *Pediatr. Nephrol.* 37 (7) (2022) 1695–1696, <https://doi.org/10.1007/s00467-022-05518-0>.
- [18] L. Negrea, B.H. Rovin, Gross hematuria following vaccination for severe acute respiratory syndrome coronavirus 2 in 2 patients with IgA nephropathy, *Kidney Int.* 99 (6) (2021) 1487, <https://doi.org/10.1016/j.kint.2021.03.002>.
- [19] O. Niel, C. Florescu, IgA nephropathy presenting as rapidly progressive glomerulonephritis following first dose of COVID-19 vaccine, *Pediatr. Nephrol.* 37 (2) (2022) 461–462, <https://doi.org/10.1007/s00467-021-05351-x>.
- [20] M. Okada, E. Kikuchi, M. Nagasawa, A. Oshiba, M. Shimoda, An adolescent girl diagnosed with IgA nephropathy following the first dose of the COVID-19 vaccine, *CEN Case Rep* 3 (2022) 1–4, <https://doi.org/10.1007/s13730-021-00679-7>.
- [21] K. Park, S. Miyake, C. Tai, M. Tseng, N.K. Andeen, V.L. Kung, Letter regarding: "A case of gross hematuria and IgA nephropathy flare-up following SARS-CoV-2 vaccination, *Kidney Int Rep* 6 (8) (2021) 2246–2247, <https://doi.org/10.1016/j.ekir.2021.06.007>.
- [22] P. Perrin, X. Bassand, I. Benotmane, N. Bouvier, Gross hematuria following SARS-CoV-2 vaccination in patients with IgA nephropathy, *Kidney Int.* 100 (2) (2021) 466–468, <https://doi.org/10.1016/j.kint.2021.05.022>.
- [23] R. Plasse, R. Nee, S. Gao, S. Olson, Acute kidney injury with gross hematuria and IgA nephropathy after COVID-19 vaccination, *Kidney Int.* 100 (4) (2021) 944–945, <https://doi.org/10.1016/j.kint.2021.07.020>.
- [24] S.E.G. Rahim, J.T. Lin, J.C. Wang, A case of gross hematuria and IgA nephropathy flare-up following SARS-CoV-2 vaccination, *Kidney Int.* 100 (1) (2021) 238, <https://doi.org/10.1016/j.kint.2021.04.024>.
- [25] V. Srinivasan, A.S. Geara, S. Han, J.J. Hogan, G. Coppock, Need for symptom monitoring in IgA nephropathy patients post COVID-19 vaccination, *Clin. Nephrol.* 97 (3) (2022) 193–194, <https://doi.org/10.5414/CN110689>.
- [26] H.Z. Tan, R.Y. Tan, J.C.J. Choo, C.C. Lim, C.S. Tan, A.H.L. Loh, C.S. Tien, P.H. Tan, K.T. Woo, Is COVID-19 vaccination unmasking glomerulonephritis? *Kidney Int.* 100 (2) (2021) 469–471, <https://doi.org/10.1016/j.kint.2021.05.009>.
- [27] T. Udagawa, Y. Motoyoshi, Macroscopic hematuria in two children with IgA nephropathy remission following Pfizer COVID-19 vaccination, *Pediatr. Nephrol.* 37 (7) (2022) 1693–1694, <https://doi.org/10.1007/s00467-022-05517-1> (Epub ahead of print).
- [28] S. Watanabe, S. Zheng, A. Rashidi, IgA nephropathy relapse following COVID-19 vaccination treated with corticosteroid therapy: case report, *BMC Nephrol.* 23 (1) (2022) 135, <https://doi.org/10.1186/s12882-022-02769-9>.
- [29] S. Yokote, H. Ueda, A. Shimizu, M. Okabe, K. Yamamoto, N. Tsuboi, T. Yokoo, IgA nephropathy with glomerular capillary IgA deposition following SARS-CoV-2 mRNA vaccination: a report of three cases, *CEN Case Rep* 3 (2022) 1–7, <https://doi.org/10.1007/s13730-022-00707-0> (Epub ahead of print).
- [30] H. Apaydin, S. Can Güven, İ. Doğan, A. Çolak, S. Erten, ANCA- positive IgA nephropathy presented as alveolar hemorrhage in a COVID-19 patient, *Ann Clin Anal Med* 12 (Suppl 2) (2021) S236–S240, <https://doi.org/10.4328/ACAM.20424>.
- [31] Y. Huang, X.J. Li, Y.Q. Li, W. Dai, T. Shao, W.Y. Liu, M. Han, G. Xu, L. Liu, Clinical and pathological findings of SARS-CoV-2 infection and concurrent IgA nephropathy: a case report, *BMC Nephrol.* 21 (1) (2020) 504, <https://doi.org/10.1186/s12882-020-02163-3>.
- [32] A. Pérez, I. Torregrosa, L. D'Marco, I. Juan, L. Terradez, M.Á. Solís, F. Moncho, C. Carda-Batalla, M.J. Forner, J.L. Gorriç, IgA-dominant infection-associated glomerulonephritis following SARS-CoV-2 infection, *Viruses* 13 (4) (2021) 587, <https://doi.org/10.3390/v13040587>.
- [33] L. Badier, A. Toledano, T. Porel, S. Dumond, J. Jougen, L. Sailler, H. Bagheri, G. Moulis, M. Lafaurie, IgA vasculitis in adult patient following vaccination by ChadOx1 nCoV-19, *Autoimmun. Rev.* 20 (11) (2021), 102951, <https://doi.org/10.1016/j.autrev.2021.102951>.
- [34] M.R. Ball-Burack, J.M. Kosovsky, A case of leukocytoclastic vasculitis following SARS-CoV-2 vaccination, *J. Emerg. Med.* (2021), <https://doi.org/10.1016/j.jemermed.2021.10.005> (Epub ahead of print).
- [35] E. Bostan, D. Gulseren, O. Gokoz, New-onset leukocytoclastic vasculitis after COVID-19 vaccine, *Int. J. Dermatol.* 60 (10) (2021) 1305–1306, <https://doi.org/10.1111/ijd.15777>.
- [36] K. Chandwar, D.G. Ekbote, J. Dixit, K. Kishor, K.P. Malhotra, U. Dhakad, IgA vasculitis post-ChAdOx1 nCoV-19 vaccine in a patient with rheumatoid arthritis, *Indian J. Rheumatol.* 17 (2) (2022) 186–187 (Epub ahead of print).
- [37] M. Fritzen, G.D.G. Funchal, M.O. Luiz, G.S. Durigon, Leukocytoclastic vasculitis after exposure to COVID-19 vaccine, *An. Bras. Dermatol.* 97 (1) (2022) 118–121, <https://doi.org/10.1016/j.abd.2021.09.003>.
- [38] M.E. Grossman, G. Appel, A.J. Little, C.J. Ko, Post-COVID-19 vaccination IgA vasculitis in an adult, *J. Cutan. Pathol.* 14 (2021), <https://doi.org/10.1111/cup.14168>, 10.1111/cup.14168.
- [39] A.M. Hines, N. Murphy, C. Mullin, J. Barillas, J.C. Barrientos, Henoch-Schönlein purpura presenting post COVID-19 vaccination, *Vaccine* 39 (33) (2021) 4571–4572, <https://doi.org/10.1016/j.vaccine.2021.06.079>.
- [40] H. Iwata, K. Kamiya, S. Kado, T. Nakaya, H. Kawata, M. Komine, M. Ohtsuki, Case of immunoglobulin A vasculitis following coronavirus disease 2019 vaccination, *J. Dermatol.* 48 (12) (2021) e598–e599, <https://doi.org/10.1111/1346-8138.16167>.
- [41] M. Kondo, K. Yamanaka, Possible HSP reactivation post-COVID-19 vaccination and booster, *Clin Case Rep* 9 (2021), e05032, <https://doi.org/10.1002/ccr3.5032>.
- [42] J.A. Maye, H.P. Chong, V. Rajagopal, V. Petchey, Reactivation of IgA vasculitis following COVID-19 vaccination, *BMJ Case Rep.* 14 (11) (2021), e247188, <https://doi.org/10.1136/bcr-2021-247188>.
- [43] M.M.B. Mohamed, T.J. Wickman, A.B. Fogo, J.C.Q. Velez, De novo immunoglobulin A vasculitis following exposure to SARS-CoV-2 immunization, *Ochsner J.* 21 (4) (2021) 395–401, <https://doi.org/10.31486/toj.21.0083>.
- [44] A. Naitilh, W. Lahlou, A. Bourial, H. Rais, N. Ismaili, I. Abousahfa, L. Belyamani, A rare case of henoch-schönlein purpura following a COVID-19 vaccine-case report, *SN Compr Clin Med* 8 (2021) 1–4, <https://doi.org/10.1007/s42399-021-01025-9>.
- [45] S. Nakatani, K. Mori, F. Morioka, C. Hirata, A. Tsuda, H. Uedono, E. Ishimura, D. Tsuruta, M. Emoto, New-onset kidney biopsy-proven IgA vasculitis after receiving mRNA-1273 COVID-19 vaccine: case report, *CEN Case Rep* 11 (3) (2022) 358–362, <https://doi.org/10.1007/s13730-021-00677-9> (Epub ahead of print).
- [46] M. Obeid, C. Fenwick, G. Pantaleo, Reactivation of IgA vasculitis after COVID-19 vaccination, *Lancet Rheumatol* 3 (9) (2021) e617, [https://doi.org/10.1016/S2665-9913\(21\)00211-3](https://doi.org/10.1016/S2665-9913(21)00211-3).
- [47] J. Oniszczuk, T. Bettuzzi, L. Anjou, V. Audard, E. Sbidian, K. El Karoui, A. Moktefi, De novo IgA vasculitis following adenovirus-based SARS-CoV-2 vaccination, *Clin Kidney J* (2021) sfab257, <https://doi.org/10.1093/ckj/sfab257>.
- [48] K. Sugita, S. Kaneko, R. Hisada, M. Harano, E. Anno, S. Hagiwara, E. Imai, M. Nagata, Y. Tsukamoto, Development of IgA vasculitis with severe glomerulonephritis after COVID-19 vaccination: a case report and literature review, *CEN Case Rep* (3) (2022) 1–6, <https://doi.org/10.1007/s13730-022-00695-1>. Epub ahead of print.
- [49] M.M. Sirufo, M. Raggiunti, L.M. Magnanini, L. Ginaldi, M. De Martinis, Henoch-Schönlein purpura following the first dose of COVID-19 viral vector vaccine: a case report, *Vaccines (Basel)* 9 (10) (2021) 1078, <https://doi.org/10.3390/vaccines9101078>.
- [50] M.O. Al Hajj, M.M.S. Migdadi, M.A.H. Aldebei, M.B.F. Jarrar, A case of Henoch-Schönlein purpura in a COVID-19 patient, *Eur. J. Biomed. Pharmaceut. Sci.* 8 (6) (2021) 161–164.
- [51] D.A. Al Ghoozi, H.M. Alkhayyat, A child with Henoch-Schönlein purpura secondary to a COVID-19 infection, *BMJ Case Rep.* 14 (1) (2021), e239910, <https://doi.org/10.1136/bcr-2020-239910>.
- [52] M. Allez, B. Denis, J.D. Bouaziz, M. Battistella, A.M. Zagdanski, J. Bayart, I. Lazaridou, C. Gatey, E. Pillebout, M.L. Chaix Baudier, C. Delaugerre, J. M. Molina, J. Le Goff, COVID-19-related IgA vasculitis, *Arthritis Rheumatol.* 72 (11) (2020) 1952–1953, <https://doi.org/10.1002/art.41428>.
- [53] L. Barbeta, G. Filocamo, E. Passoni, F. Boggio, C. Folli, V. Monzani, Henoch-Schönlein purpura with renal and gastrointestinal involvement in course of COVID-19: a case report, *Clin. Exp. Rheumatol.* 39 (2021) 191–192. Suppl 129(2).
- [54] O.E. Bekhit, A.A. Alfatani, M.H. Eid, S.A. Mohamed, Childhood immunoglobulin A vasculitis associated with COVID-19: a case report, *J Child Sci* 11 (1) (2021) e218–e221.
- [55] C. Borocco, C. Lafay, I. Plantard, et al. SARS-CoV-2-associated Henoch-Schönlein purpura in a 13-year-old girl. *Arch. Pediatr.* 28, 7, 202. 573–575. 10.1016/j.arcped.2021.06.004.

- [56] G. El Hasbani, A.T. Taher, A.S.M. Jawad, I. Uthman, Henoch-Schönlein purpura: another COVID-19 complication, *Pediatr. Dermatol.* 38 (5) (2021) 1359–1360, <https://doi.org/10.1111/pde.14699>.
- [57] S. Falou, G. Kahil, B. AbouMerhi, R. Dana, I. Chokr, Henoch Schonlein Purpura as possible sole manifestation of COVID-19 in children, *Acta Sci Paediatr* 4 (4) (2021) 27–29.
- [58] G.P.D. Gogeaescoechea, V.L.A. Aparicio, IgA vasculitis associated with Covid-19 infection in a pediatric patient, a case report, *Rev Parag Reumatol* 7 (1) (2022) 27–31, <https://doi.org/10.18004/rpr/2021.07.01.27>.
- [59] M. Jacobi, H.M. Lancrei, T. Brosh-Nissimov, Y. Yeshayahu, Purpurona: a novel report of COVID-19-related Henoch-Schonlein Purpura in a child, *Pediatr. Infect. Dis. J.* 40 (2) (2021) e93–e94, <https://doi.org/10.1097/INF.0000000000003001>.
- [60] P.M. Jedlowski, M.F. Jedlowski, Coronavirus disease 2019-associated immunoglobulin A vasculitis/Henoch-Schönlein purpura: a case report and review, *J. Dermatol.* 49 (1) (2022) 190–196, <https://doi.org/10.1111/1346-8138.16211>.
- [61] G. Kumar, S. Pillai, P. Norwick, H. Bukulmez, Leucocytoclastic vasculitis secondary to COVID-19 infection in a young child, *BMJ Case Rep.* 14 (4) (2021), e242192, <https://doi.org/10.1136/bcr-2021-242192>.
- [62] N.L. Li, A.B. Papini, T. Shao, L. Girard, Immunoglobulin-A vasculitis with renal involvement in a patient with COVID-19: a case report and review of acute kidney injury related to SARS-CoV-2, *Can J Kidney Health Dis* 8 (2021), 2054358121991684, <https://doi.org/10.1177/2054358121991684>.
- [63] M.D. Nakandakari, H. Marín-Macedo, R. Seminario-Vilca, IgA vasculitis (henoch schönlein purpura) in a pediatric patient with covid-19 and strongyloidiasis. case report, *Rev Fac Med Hum* 21 (1) (2021) 199–205, <https://doi.org/10.25176/RFMH.v21i1.3265>.
- [64] I. Oñate, M. Ortiz, A. Suso, C. Mon, K. Galindo, C. Lentisco, R. Camacho, M. Sánchez, A. Oliet, O. Ortega, J.C. Herrero, J.A. Cortés, A. Pascual, IgA vasculitis with nephritis (Henoch-Schönlein purpura) after COVID-19: a case series and review of the literature, *Nefrología* 42 (4) (2021) 481–489, <https://doi.org/10.1016/j.nefro.2021.07.009> (Epub ahead of print).
- [65] S. Riscassi, M.A. Kalapurackal, L. Battisti, K. Eisendle, B. Raffener, F. Mercolini, Vasculitis in a child with COVID-19: a novel presentation of henoch-schönlein purpura, *Klin. Pädiatr.* 234 (2) (2022 Mar) 116–118, <https://doi.org/10.1055/a-1532-2243>.
- [66] S. Sandhu, S. Chand, A. Bhatnagar, R. Dabas, S. Bhat, H. Kumar, P.K. Dixit, Possible association between IgA vasculitis and COVID-19, *Dermatol. Ther.* 34 (1) (2021), e14551, <https://doi.org/10.1111/dth.14551>.
- [67] Z. Savas Sen, G. Tanir, R. Gumuser Cinni, M. Uysal Yazici, T. Yoldas, Z. Ozturk, M. H. Kizilkaya, S. Ozdem, R. Yalcinkaya, C. Ozturk, A. Yuze Sezen, S. Ozdel, B. E. Derinkuyu, M. Polat, F.N. Oz, Multisystem inflammatory syndrome in children during severe acute respiratory syndrome coronavirus-2 pandemic in Turkey: a single-centre experience, *J. Paediatr. Child Health* 58 (1) (2022) 129–135, <https://doi.org/10.1111/jpc.15674>.
- [68] J. Serafinelli, A. Mastrangelo, W. Morello, V.F. Cerioni, A. Salim, M. Nebuloni, G. Montini, Kidney involvement and histological findings in two pediatric COVID-19 patients, *Pediatr. Nephrol.* 36 (11) (2021) 3789–3793, <https://doi.org/10.1007/s00467-021-05212-7>.
- [69] S. Soleiman-Meigooni, R. Hamidi-Farahani, M. Ahmadi, A. Asgari, R. Yaghmaee, Henoch-Schönlein Purpura following Severe Acute Respiratory Syndrome Coronavirus-2 infection: a case report and short review of histopathological changes in dermis, *Authorea Preprints* (2021), <https://doi.org/10.22541/au.161148965.52528385/v1>.
- [70] A.S. Suso, C. Mon, I. Oñate Alonso, K. Galindo Romo, R.C. Juarez, C.L. Ramírez, M. Sánchez Sánchez, V. Mercado Valdivia, M. Ortiz Librero, A. Oliet Pala, O. Ortega Marcos, J.C. Herrero Berron, N. Silvestre Torner, M. Alonso Riaño, A. Pascual Martin, IgA vasculitis with nephritis (Henoch-Schönlein purpura) in a COVID-19 patient, *Kidney Int Rep* 5 (11) (2020) 2074–2078, <https://doi.org/10.1016/j.ekir.2020.08.016>.
- [71] S. Traidl, Y. Angela, A. Kapp, M. Schefzyk, Hemorrhagic rash on the legs, *JAAD Case Rep* 12 (2021) 67–69, <https://doi.org/10.1016/j.jcdr.2021.04.015>.
- [72] R. Ziyara, A. Thompson, B. Liu, Henoch-Schönlein purpura in a COVID-19-positive child with abdominal pain and PIMS-TS, *Clin. Pediatr.* 61 (1) (2022) 5–8, <https://doi.org/10.1177/00099228211040660>.
- [73] M.P. Cheng, C.P. Yansouni, N.E. Basta, M. Desjardins, S. Kanjilal, K. Paquette, C. Caya, M. Semret, C. Quach, M. Libman, L. Mazzola, J.A. Sacks, S. Dittrich, J. Papenburg, Serodiagnostics for severe acute respiratory syndrome-related coronavirus 2: a narrative review, *Ann. Intern. Med.* 173 (6) (2020) 450–460, <https://doi.org/10.7326/M20-2854>.
- [74] A. Zuiani, D.R. Wesemann, Antibody dynamics and durability in Coronavirus disease-19, *Clin. Lab. Med.* 42 (1) (2022) 85–96, <https://doi.org/10.1016/j.cll.2021.10.004>.
- [75] A.V. Wisniewski, J. Campillo Luna, C.A. Redlich, Human IgG and IgA responses to COVID-19 mRNA vaccines, *PLoS One* 16 (6) (2021), e0249499, <https://doi.org/10.1371/journal.pone.0249499>.
- [76] U. Kaya Akca, E. Atalay, M.K. Cuceoglu, Z. Balik, S. Sener, Y. Ozsurekci, O. Basaran, E.D. Batu, Y. Bilginer, S. Ozen, Impact of the COVID-19 pandemic on the frequency of the pediatric rheumatic diseases, *Rheumatol. Int.* 42 (1) (2022) 51–57, <https://doi.org/10.1007/s00296-021-05027-7>.
- [77] M.Z. Salleh, M.N. Norazmi, Z.Z. Deris, Immunogenicity mechanism of mRNA vaccines and their limitations in promoting adaptive protection against SARS-CoV-2, *PeerJ* 10 (2022), e13083, <https://doi.org/10.7717/peerj.13083>.
- [78] M. Doherty, What value case reports? *Ann. Rheum. Dis.* 53 (1) (1994) 1–2, <https://doi.org/10.1136/ard.53.1.1>.
- [79] M. Irwin, B. Lazarevic, D. Soled, A. Adesman, The COVID-19 pandemic and its potential enduring impact on children, *Curr. Opin. Pediatr.* 34 (1) (2022) 107–115, <https://doi.org/10.1097/MOP.0000000000001097>.